Injury 54 (2023) 111096

Contents lists available at ScienceDirect

Injury

journal homepage: www.elsevier.com/locate/injury

Do we need to fix the anterior fracture component in insufficiency fractures of the pelvis? A biomechanical comparison on an FFP type IIIc fracture in an osteoporotic pelvic bone model

Charlotte Arand [a,*], Dorothea Mehler [a], Anne Sauer [a], Christian Hartung [a], Erol Gercek [a], Pol M. Rommens [a], Daniel Wagner [a,b]

[a] Department of Orthopaedics and Traumatology, University Medical Center Mainz, Langenbeckstraße 1, Mainz 55131, Germany
[b] Department of Orthopedics and Trauamtology, Lausanne University Hospital, Rue du Bugnon 46, 1011 Lausanne, Switzerland

ARTICLE INFO

Keywords:
Fragility fracture
Insufficiency fracture
Pelvic ring fracture
Minimal invasive stabilization
Biomechanical evaluation

ABSTRACT

There is a growing understanding of the specific characteristics of insufficiency fractures of the pelvis and of general requirements for the treatment of affected patients with focus on early mobilization and effective pain reduction as the main goals of therapy. While there is consensus on the significance of achieving stability of the dorsal pelvic ring structures there is still an open discussion about the potential benefits of additional stabilization of an anterior fracture component.

Within a biomechanical test setup, two established methods of dorsal fracture fixation were tested under axial loading (25–1200 N; 1000 test cycles) on an explicit osteoporotic bone model ($n = 32$) with a standardized FFP type IIIc fracture with and without additional fixation of the anterior fracture component. Dorsal fixation was performed with and long and a short 7.3 mm cannulated screw in S1 in one group ($n = 16$), and a trans sacral bar with an additional short 7.3 mm cannulated screw in S1 in the other group ($n = 16$). Half of the samples received a 7.3 mm cannulated retrograde transpubic screw for anterior fixation.

The fixation with the trans sacral bar and the additional anterior screw fixation showed the highest rate of stability ($p = 0.0014$), followed by the double SI-screw fixation with stabilization of the anterior fracture ($p = 0.0002$). During testing, we observed the occurrence of new sacral fractures contralateral to the initial fracture in 22/32 samples.

The results let us assume that stabilization of an additional anterior fracture component relevantly improves the stability of the entire ring construct and might prevent failure of the dorsal stabilization or further fracture progression.

Introduction

We observe an increasing incidence of fragility fractures of the pelvis (FFP) especially in patients older than 65 years [1–3]. Affected patients suffer from pain, which often leads to significantly reduced mobility. The primary objective of therapy is sufficient pain reduction to allow for early remobilization in order to prevent common complications like pneumonia, muscular atrophy, uncertain gait and persisting immobility with subsequent loss of independency [1,4–6]). During the past decades the clinical characteristics and specific requirements for treatment of these fractures have been examined and well described. New and specific classification systems were implemented as the Fragility Fractures of the Pelvis Classification (FFP) by Rommens and Hofmann [7], the Alpha Numeric Classification system (ANC) by Krappinger et al. [8] and the OF-pelvis Classification system of osteoporotic sacral and pelvic ring fractures by Ullrich et al. [9] to specify the individual fracture and also to guide early treatment decisions. Analgetic therapy and physiotherapeutic mobilization is recommended for isolated anterior (FFP I) and non-displaced dorsal fractures (FFP II) [7]. Dorsally displaced fractures (FFP III and FFP IV) and patients with prolonged pain or immobilization were recommended for surgical intervention [10]. Fracture progression was observed in 14 % of patients with FFP [7], which also included the progression from a unilateral to a bilateral dorsal pelvic fracture [7,8]. Increased shear forces due to interruption of the ring construct are

* Corresponding author.
E-mail address: charlotte.arand@unimedizin-mainz.de (C. Arand).

https://doi.org/10.1016/j.injury.2023.111096
Accepted 2 October 2023
Available online 5 October 2023
0020-1383/© 2023 The Authors. Published by Elsevier Ltd. This is an open access article under the CC BY license (http://creativecommons.org/licenses/by/4.0/).

considered as the predominant reason [11].

In operatively treated patients, minimally invasive procedures and percutaneous fixation techniques are favored for these typically frail patients. In contrast to young patients with pelvic ring fractures after high-energy trauma, the goal of the operative treatment is not an anatomical reduction but an in situ fixation and stabilization to achieve sufficient pain relief [12,13].

Established operative methods for the treatment of FFP include different percutaneous (trans-) iliosacral fixation techniques [14–21] and the trans-iliac internal fixator for stabilization of the posterior pelvic ring [22–25]. For the anterior fracture, internal [26] or external fixator [27], minimally invasive percutaneous screw fixation of the ramus superior ossis pubis [28], or open reduction and plate osteosynthesis are commonly used [29].

The discussion is ongoing if an anterior fixation is essential in FFP if the posterior fracture component is sufficiently stabilized. On the one hand, additional anterior fixation can reduce pain in the groin region, and can enhance overall stability. On the other hand, the additional incision provides more risks of affecting vulnerable structures as nerves, blood vessels and the urinary bladder, as well as wound infection, and prolongs operation and anesthesia time [30,31]. Further, implant-related complications are reported like implant loosening due to reduced bone quality, especially after plate osteosynthesis [29]. Currently, the question remains if the benefit of an additional anterior surgical approach outweighs its risks.

The motivation of the present study was the biomechanical evaluation of the potential benefit of an additional anterior fixation regarding stability after posterior fixation of an FFP IIIc fracture of the pelvic ring on an osteoporotic bone model.

Materials and method

During a pre-study three different synthetic bone models (Fa. Synbone Type 4060 [32], Fa. Synbone Type 4900 and Fa. Sawbone Type 1301–1), each of them designated by the producer to be osteoporotic, underwent pull-out tests. Therefore, a semi-threaded 7.3 mm screw was introduced trans-iliacal into the cancellous bone of the body of S1. The thread of the screw was positioned in the body of S1, while the head of the screw had at least a 3 cm distance to the lateral cortex of the ilium. Three bone models from each type were prepared this way. Position of the screw was confirmed radiographically in three views (ap view, inlet and outlet view). With a servo-pneumatic test machine continuously increasing pulling force was applied to the screw head with the force vector corresponding to the screw axis. The test machine detected and recorded the force at the moment of screw pull-out. According to these pre-testings, the bone model Sawbone Type 1301–1 (Fa. Sawbones, Sawbones Europe AB Servicing Europe, Middle East, and Africa, Krossverksgatan 3, 216 16 Malmö, Sweden) was chosen for further tests [33,34].

A 3D printed sawing template was generated to create a standardized fracture pattern with identical fracture location in each single artificial bone. In order to simulate an FFP type IIIc fracture, a complete fracture of the sacral ala was generated on the left side lateral to the neuroforamina. A standardized vertical-oblique fracture of the superior and inferior pubic ramus was generated also on the left side in the area of the obturator foramen, consistent with a Naketani II fracture [35]. A 3 mm thick felt was placed into the fracture gap to simulate a partially unstable fracture. To achieve optimum comparability standardized position of the implants was achieved by using customized 3D printed drilling templates which were calculated previously on the CAD data set of the bone model. The drilling guides follow a straight trans-iliosacral corridor in S1 and an additional, slightly oblique corridor in S1 ending in the area of the promontory of S1. A separate drilling guide defines the corridor for a retrograde transpubic screw for fixation of the anterior fracture component ending up in the cortical bone of the lateral ilium.

Four groups of eight artificial pelvic bones each were prepared. In all 32 bones, implant corridors in S1 were prepared using the drill guides. In 16 bones the anterior corridor for the retrograde transpubic screw was prepared as well. Preparation of the corridors included introduction of a guide wire using the customized drilling guides and over drilling the guide wire afterwards with a cannulated 5.0 mm drill. All drilling was performed before generation of the fracture to guarantee for standardized reposition afterwards. After removal of the guide wires the fracture was generated by using the 3D printed saw guide and an oscillating saw.

Sixteen of the pelvic bones were fixated with a trans-sacral bar in S1 according to the implantation technique described by Mehling and Hessmann [18,20]. With this implant, a slight compression of the sacral fracture was created through carefully bilateral tightening of the nuts with washers against the lateral wall of the posterior ilium. An additional short 7.3 mm fully-threaded ilio-sacral screw with washer was implanted, following the prepared corridor by crossing the fracture and ending up in the area of the promontory (Fig. 1).

The remaining 16 bones models were then fixated with a cannulated 7.3 mm semi-threaded trans-iliosacral screw (140/32 mm) with washer in S1 following the same pre-drilled corridor as the trans-sacral bar starting from the left lateral ilium passing right through the right sacroiliac joint. In addition, a 7.3 mm fully-threaded screw with washer was introduced in S1 as well, following the prepared corridor by crossing the fracture and ending up in the area of the promontory (Fig. 2). The insertion of the long trans-iliosacral screw was performed first in order to create a slight compression on the fracture site as in the trans-sacral bar group.

In each group, eight bones received an anterior screw fixation with a cannulated 7.3 mm semi-threaded screw following the prepared transpubic corridor in retrograde version (Figs. 1a–c, 2a–c). The other eight bone models were left without an anterior stabilization (Figs. 1d–f, 2d–f).

Groups were named as: trans-sacral sacro-iliac screw with anterior fixation (SI+), trans-sacral sacro-iliac screw without anterior fixation (SI-); trans-sacral bar with anterior fixation (SB+), trans-sacral bar without anterior fixation (SB-).

All bones were checked radiographically for correct implant positioning after stabilization in ap, inlet and outlet view (Figs. 1, 2).

The bones were attached to a servo-pneumatic test machine over the endplate of S1 and set on to two fixed bipolar hip protheses building up a counterfort, simulating a standing position (Fig. 3). Orientation of the pelvis was adjusted in a way, so that the pelvic tilt was about 15° and axial loading could be performed with a minimum of shear forces.

Axial loading was then performed force-controlled on the endplate of S1. Cyclic axial loading forces were applied with 25 - 1200 N for a total of 1000 test cycles with a frequency of 0.1 Hz. Fracture zones were observed and followed with an optical tracking system. Further, the translation of the lever arm of the test machine that was needed to generate the demanded forces was measured. Testing was interrupted and finished early in case of breakdown of the bone, or if the measured translation of the level arm overreached 25 mm. The marge of 25 mm was set because fracture occurrence was observed during pre-testing on non-fractured bones under a cyclic loading ramp at a translation range > 25 mm.

Statistical evaluation was performed using GraphPad Prism (Prism 9.5.1, GraphPad Software, 225 Franklin Street. Fl. 26, Boston, MA 02,110, USA) applying Mann-Whitney-U test and Kruskal-Wallis test.

Results

Ten of the 32 bones finished the test according to the protocol reaching 1000 cycles. In the group fixed with trans-sacral bar and S1 screw and the additional retrograde trans-pubic screw, 7 of 8 constructs finished the test. Within the group stabilized with the long semi-threaded trans-sacral screw and the S1 screw with an anterior screw fixation, 2 of 8 constructs finished the 1000 loading cycles. In the group stabilized with the trans-sacral bar without fixation of the anterior pelvic

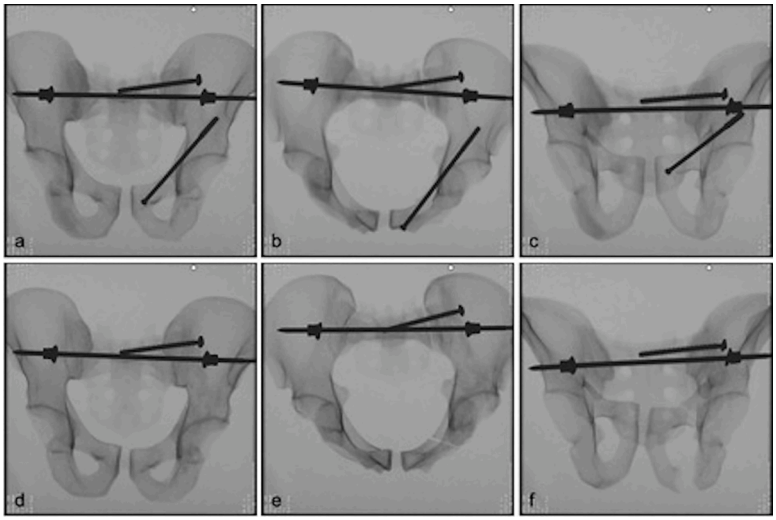

Fig. 1. X-ray control of implant position in the sacral bar group with (a–c) and without (d–f) anterior screw fixation in ap (a, d), inlet (b, e) and outlet-projection (c, f).

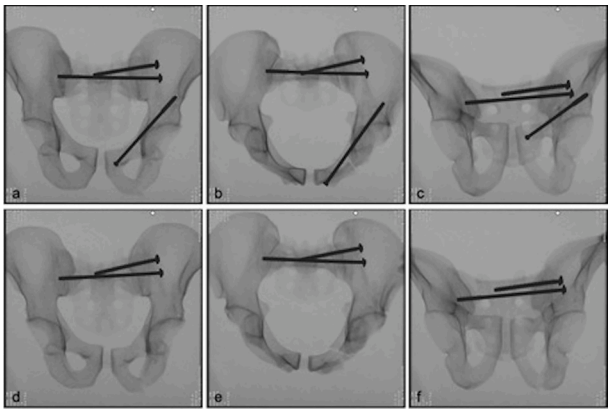

Fig. 2. X-ray control of implant position in the SI-screw group with (a–c) and without (d–f) anterior screw fixation in ap (a, d), inlet (b, e) and outlet-projection (c, f).

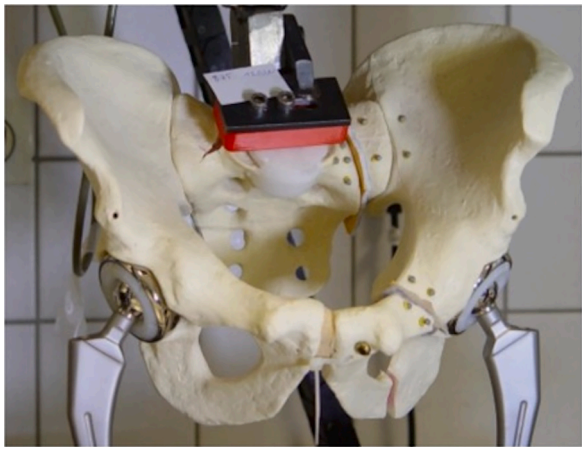

Fig. 3. Test setup with the bone model set on two fixed bipolar hip protheses and connected to the lever arm of the servo-pneumatic test machine via end-plate of S1.

ring fracture, only one of the constructs completed the test, while within the group of the semi-threaded trans-sacral screw without anterior stabilization, none of the test samples finished the 1000 test cycles. The group of the trans-sacral bar with anterior stabilization showed the highest stability ($p = 0{,}0238$), followed by the group of the trans-sacral screw with fixation of the anterior fracture. Statistical analysis was performed applying Mann-Whitney-U test and Kruskal-Wallis test. Table 1 shows the reached number of loading cycles in detail, Fig. 4 provides a graphical overview on the reached loading cycles.

Discussion

Treatment of osteoporotic pelvic fractures remains a challenge as the patients suffering from those injuries are typically frail and often bear relevant comorbidities. To avoid permanent immobility and loss of a self-determinated life, the first priority for treatment of those fractures is early remobilization. If the patient cannot be remobilized despite adequate analgesic therapy, operative stabilization is considered. The goals for the surgical treatment are to provide sufficient stability and to be as minimally-invasive as possible [36]. Specific classification systems for osteoporotic and insufficiency fractures of the pelvic ring, such as the FFP classification by Rommens and Hofmann [7] and within the last year the OF classification [9] (following the corresponding classification system for vertebral body fractures), have led to a new and enhanced understanding of these pathologies. In addition, specific

Table 1
reached number of test cycles of each single bone. SI+ = SI-screws with anterior fixation, SI- = SI-screws without anterior fixation; SB + = sacral bar with anterior fixation, SB- = sacral bar without anterior fixation. * marks the occurrence of a new fracture.

	SI +	SI -	SB +	SB -
1	1000	46*	1000	133*
2	355*	9*	1000	363*
3	900*	1*	1000	50*
4	953*	67*	573*	125*
5	542*	1*	1000	25*
6	825*	203*	1000	1000
7	1000	58*	1000	18*
8	565*	36*	1000	170*
median (range)	862.5 (645)	41.0 (202)	1000 (427)	129.0 (982)
percentile 25 %/75 %	547.5/988.3	3.0/64.8	1000.0/1000.0	31.3/314.8

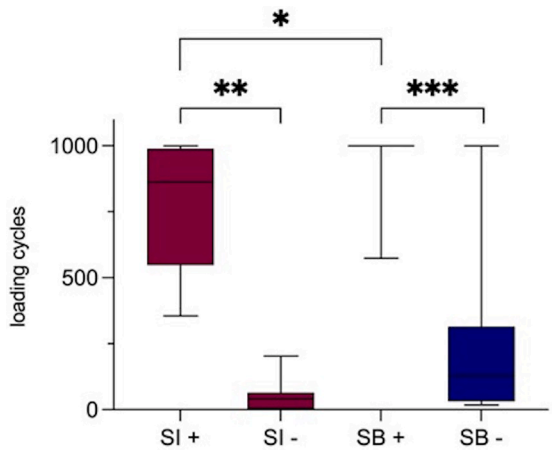

Fig. 4. graphic overview on the reached loading cycles. SI+ = SI-screws with anterior fixation, SI- = SI-screws without anterior fixation; SB + = sacral bar with anterior fixation, SB- = sacral bar without anterior fixation. Comparison show statistical significant differences: * SI + vs. SB + $p = 0.0238$; ** SI + vs. SI - $p = 0.0002$; *** SB + vs. SB - $p = 0.0014$.

recommendations for adequate treatment can be suggested in relation to the fracture type [37]. Nevertheless, the discussion about how to address those fractures in case of an operative treatment remains controversial. While the stabilization of the dorsal part of the pelvic ring is uncontroversial, the question remains if the stabilization of an additional anterior pelvic ring fracture is necessary or at all beneficial, or if it is not of essential importance.

In our study, we evaluated the effects of a potential weight on the stability of an additional screw fixation of the anterior pelvic ring fracture in an FFP type IIIc model within a standardized biomechanical test setup with repetitive axial loading. Our results showed significantly higher stability in the bone models with additional fixation of the anterior fracture. Furthermore, we observed a significantly reduced rate of loss of stability within the group stabilized with trans-sacral bar as compared to the group with the two SI screws. Under cyclic axial loading, we observed new sacral fractures on the contralateral side of the initial fracture to occur more frequently and earlier during testing in the bone models without anterior fixation.

There are several limitations of this study to mention. Testing was performed on synthetic bone models. Even if a specific osteoporotic bone model was chosen the artificial sawbone does not fully simulate the individual physiological variability of bone mineral density within the pelvic bone. Furthermore, secondary stabilizers as muscles and especially the strong peripelvic ligaments like the pectineal ligament and the iliolumbar ligaments are missing within this model. Therefore, construct stability might be underestimated in our study.

As another limitation it is to state that within our test setup an upright stand with only symmetric axial loading was simulated. Tensile forces and asymmetric loading as they occur during walking were not reproduced.

In the literature we find a controversial discussion about fixation of the anterior fracture component in fragility fractures of the pelvis without clear conclusion or recommendation.

Wilson et al. reported in a detailed review about the operative management of FFP that results of anterior fracture fixation to be very variable [38]. The review evaluated 17 studies with a total of 766 patients of which 463 were treated surgically. In 70 % of the operated patients, no anterior fixation was performed at all, even if there was an anterior fracture [39–41]. Osterhoff et al. investigated the impact of the pectineal ligament as a secondary stabilizer on anterior pelvic ring fractures within a biomechanical study on cadaveric hemipelves and showed a significant loss of stability in case of injury of the pectineal ligament [42]. In most of the cases, the ligament can be assumed to be intact in osteoporotic fractures, except when a relevant dislocation of the anterior fracture component is present or the fracture is the result of a relevant trauma mechanism.

In contrast, there are many studies found in literature evaluating different operative treatment strategies for stabilization of the anterior fracture component in FFP. Sufficient pain relief was reported to be achieved using a supraacetabular external fixator additional to the posterior fixation. However, a relatively high complication rate was associated with this method including difficult mobilization of the patient due to extensive hardware [43,44]. Internal fixation with the usage of an internal fixator system consisting of a subcutaneous, curved rod connecting the supra-acetabular fixator pins or screws was described to be associated with a high complication rate involving the femoral vessels and nerves at risk [30,31,45].

Percutaneous screw fixation of the anterior pelvic ring can be performed in antegrade and retrograde direction and was described as a sufficient and minimally invasive fixation method for the treatment of anterior pelvic ring fractures without relevant displacement [28,46]. Mosheiff et al. reported about a method to address even displaced fractures with percutaneous screw fixation using a special maneuver [47]. With a low intraoperative complication rate, percutaneous transpubic screw fixation is a relatively safe method, but implant-related complications, i.e. painful soft tissue irritation due to implant loosening in the weak bone and backing out of the screw, were described. Also, screw positioning is not always possible due to narrowness and curvature of the screw corridor [48].

Acklin et al. investigated different ways of screw and plate fixation of the anterior pelvic ring in a biomechanical bone on human cadaveric hemipelves with reduced bone mineral density [49,50] and found two 3.5 mm screws to provide comparable stability to a 7.3 mm screw. Within this study, the authors showed plate osteosynthesis to be superior over screw fixation regarding primary stability. However, plate osteosynthesis is associated with a higher invasiveness of the surgical procedure and should be limited to displaced fractures [29].

Herteleer et al. described in a retrospective analysis of a total of 48 patients with FFP treated with single plate osteosynthesis of the anterior pelvic ring in 37 cases, and double plate osteosynthesis in 11 cases, an overall high rate of screw loosening that occurred more frequently and earlier in cases of single plate osteosynthesis [29].

Conclusion

Our observations suggest that

(1) the fixation of the anterior fracture improves the stability of the whole pelvic ring construct significantly;
(2) trans-sacral bar fixation enhanced with an iliosacral screw in S1 and a retrograde trans-pubic screw provides the highest stability within our collective;
(3) in case of operative treatment of a unilateral fracture of the dorsal pelvic ring a prophylactic stabilization of the uninjured contralateral aspect might be beneficial and should be considered with respect to the risk of potential fracture progression. To investigate the effects of a prophylactic stabilization of the uninjured side, further evaluations and testing are warranted.

Declaration of Competing Interest

None.

Acknowledgments

We acknowledge the support and funding of “Mainzer Trauma-Stiftung”. Parts of the presented data will be subject of Christian Hartung’s doctoral thesis.

References

[1] Burge R, Dawson-Hughes B, Solomon DH, Wong JB, King A, Tosteson A. Incidence and economic burden of osteoporosis-related fractures in the United States, 2005-2025. J Bone Miner Res 2007;22(3):465–75.
[2] Oberkircher L, Ruchholtz S, Rommens PM, Hofmann A, Bucking B, Kruger A. Osteoporotic pelvic fractures. Dtsch Arztebl Int 2018;115(5):70–80.
[3] Rollmann MF, Herath SC, Kirchhoff F, Braun BJ, Holstein JH, Pohlemann T, et al. Pelvic ring fractures in the elderly now and then - a pelvic registry study. Arch Gerontol Geriatr 2017;71:83–8.
[4] van Dijk WA, Poeze M, van Helden SH, Brink PR, Verbruggen JP. Ten-year mortality among hospitalised patients with fractures of the pubic rami. Injury 2010;41(4):411–4.
[5] Beliveau MM, Multach M. Perioperative care for the elderly patient. Med Clin North Am 2003;87(1):273–89.
[6] Siu AL, Penrod JD, Boockvar KS, Koval K, Strauss E, Morrison RS. Early ambulation after hip fracture: effects on function and mortality. Arch Intern Med 2006;166(7):766–71.
[7] Rommens PM, Hofmann A. Comprehensive classification of fragility fractures of the pelvic ring: recommendations for surgical treatment. Injury 2013;44(12):1733–44.
[8] Krappinger D, Kaser V, Merkel A, Neururer S, Lindtner RA. An alphanumeric classification of osteoporotic pelvic ring injuries. Arch Orthop Trauma Surg 2021;141(5):861–9.
[9] Ullrich BW, Schnake KJ, Spiegl UJA, Schenk P, Mendel T, Behr L, et al. OF-Pelvis classification of osteoporotic sacral and pelvic ring fractures. BMC Musculoskelet Disord 2021;22(1):992.
[10] Rommens PM, Hopf JC, Arand C, Handrich K, Boudissa M, Wagner D. Prospective assessment of key factors influencing treatment strategy and outcome of fragility fractures of the pelvis (FFP). Eur J Trauma Emerg Surg 2022;48(4):3243–56.
[11] Mendel T, Ullrich BW, Hofmann GO, Schenk P, Goehre F, Schwan S, et al. Progressive instability of bilateral sacral fragility fractures in osteoporotic bone: a retrospective analysis of X-ray, CT, and MRI datasets from 78 cases. Eur J Trauma Emerg Surg 2021;47(1):11–9.
[12] Heiman E, Gencarelli P, Tang A, Yingling JM, Liporace FA, Yoon RS. Fragility Fractures of the Pelvis and Sacrum: current Trends in Literature. Hip Pelvis 2022;34(2):69–78.
[13] Rommens PM. Paradigm shift in geriatric fracture treatment. Eur J Trauma Emerg Surg 2019;45(2):181–9.
[14] Rommens PM. Fragility fractures of the pelvis. 1st ed. New York, NY: Springer Berlin Heidelberg; 2017. pages cm p.
[15] van Zwienen CM, van den Bosch EW, Snijders CJ, Kleinrensink GJ, van Vugt AB. Biomechanical comparison of sacroiliac screw techniques for unstable pelvic ring fractures. J Orthop Trauma 2004;18(9):589–95.
[16] Hartensuer R, Lodde MF, Keller J, Eveslage M, Stolberg-Stolberg J, Riesenbeck O, et al. Safety, effect and feasibility of percutaneous si-screw with and without augmentation-a 15-year retrospective analysis on over 640 screws. J Clin Med 2020;9(8).
[17] Zderic I, Wagner D, Schopper C, Lodde M, Richards G, Gueorguiev B, et al. Screw-in-screw fixation of fragility sacrum fractures provides high stability without loosening-biomechanical evaluation of a new concept. J Orthop Res 2021;39(4):761–70.
[18] Mehling I, Hessmann MH. Rommens PM. Stabilization of fatigue fractures of the dorsal pelvis with a trans-sacral bar. Operative technique and outcome. Injury 2012;43(4):446–51.
[19] Sciubba DM, Wolinsky JP, Than KD, Gokaslan ZL, Witham TF, Murphy KP. CT fluoroscopically guided percutaneous placement of transiliosacral rod for sacral insufficiency fracture: case report and technique. AJNR Am J Neuroradiol 2007;28(8):1451–4.
[20] Wagner D, Kisilak M, Porcheron G, Kramer S, Mehling I, Hofmann A, et al. Trans-sacral bar osteosynthesis provides low mortality and high mobility in patients with fragility fractures of the pelvis. Sci Rep 2021;11(1):14201.
[21] Rommens PM, Wagner D, Arand C, Boudissa M, Hopf J, Hofmann A. [Minimally invasive stabilization of fragility fractures of the pelvis with transsacral bar and retrograde transpubic screw]. Oper Orthop Traumatol 2022;34(2):153–71.
[22] Dienstknecht T, Berner A, Lenich A, Nerlich M, Fuechtmeier B. A minimally invasive stabilizing system for dorsal pelvic ring injuries. Clin Orthop Relat Res 2011;469(11):3209–17.
[23] Maki S, Nakamura K, Yamauchi T, Suzuki T, Horii M, Kawamura K, et al. Lumbopelvic fixation for sacral insufficiency fracture presenting with sphincter dysfunction. Case Rep Orthop 2019;2019:9097876.
[24] Rommens PM, Arand C, Thomczyk S, Handrich K, Wagner D, Hofmann A. [Fragility fractures of the pelvis]. Unfallchirurg 2019;122(6):469–82.
[25] Muller F, Fuchtmeier B. A systematic review of the transiliac internal fixator (TIFI) for posterior pelvic injuries. SICOT J 2021;7:40.
[26] Yin Y, Luo J, Zhang R, Li S, Jiao Z, Zhang Y, et al. Anterior subcutaneous internal fixator (INFIX) versus plate fixation for pelvic anterior ring fracture. Sci Rep 2019;9(1):2578.
[27] Schuetze K, Eickhoff A, Dehner C, Blidon A, Gebhard F, Richter PH. Short-term outcome of fragility fractures of the pelvis in the elderly treated with screw osteosynthesis and external fixator. Eur J Trauma Emerg Surg 2022;48(3):2413–20.
[28] Rommens PM, Graafen M, Arand C, Mehling I, Hofmann A, Wagner D. Minimal-invasive stabilization of anterior pelvic ring fractures with retrograde transpubic screws. Injury 2019.
[29] Herteleer M, Boudissa M, Hofmann A, Wagner D, Rommens PM. Plate fixation of the anterior pelvic ring in patients with fragility fractures of the pelvis. Eur J Trauma Emerg Surg 2022;48(5):3711–9.
[30] Fang C, Alabdulrahman H, Pape HC. Complications after percutaneous internal fixator for anterior pelvic ring injuries. Int Orthop 2017;41(9):1785–90.
[31] Hesse D, Kandmir U, Solberg B, Stroh A, Osgood G, Sems SA, et al. Femoral nerve palsy after pelvic fracture treated with INFIX: a case series. J Orthop Trauma 2015;29(3):138–43.
[32] Lodde MF, Katthagen JC, Schopper CO, Zderic I, Richards G, Gueorguiev B, et al. Biomechanical comparison of five fixation techniques for unstable fragility fractures of the pelvic ring. J Clin Med 2021;10(11).
[33] Oberkircher L, Masaeli A, Bliemel C, Debus F, Ruchholtz S, Kruger A. Primary stability of three different iliosacral screw fixation techniques in osteoporotic cadaver specimens-a biomechanical investigation. Spine J 2016;16(2):226–32.
[34] Grechenig S, Gansslen A, Gueorguiev B, Berner A, Muller M, Nerlich M, et al. PMMA-augmented SI screw: a biomechanical analysis of stiffness and pull-out force in a matched paired human cadaveric model. Injury 2015;46(Suppl 4):S125–8.
[35] Starr AJ, Nakatani T, Reinert CM, Cederberg K. Superior pubic ramus fractures fixed with percutaneous screws: what predicts fixation failure? J Orthop Trauma 2008;22(2):81–7.
[36] Wilson DGG, Kelly J, Rickman M. Operative management of fragility fractures of the pelvis - a systematic review. BMC Musculoskelet Disord 2021;22(1):717.
[37] Rommens PM, Ossendorf C, Pairon P, Dietz SO, Wagner D, Hofmann A. Clinical pathways for fragility fractures of the pelvic ring: personal experience and review of the literature. J Orthop Sci 2015;20(1):1–11.
[38] Leclerc D, Wilson A, Dumas R, Gafuik C, Song D, Watkins D, et al. Cloning and mapping of a cDNA for methionine synthase reductase, a flavoprotein defective in patients with homocystinuria. Proc Natl Acad Sci U S A 1998;95(6):3059–64.
[39] Collinge CA, Crist BD. Combined percutaneous iliosacral screw fixation with sacroplasty using resorbable calcium phosphate cement for osteoporotic pelvic fractures requiring surgery. J Orthop Trauma 2016;30(6):e217–22.
[40] Hopf JC, Krieglstein CF, Muller LP, Koslowsky TC. Percutaneous iliosacral screw fixation after osteoporotic posterior ring fractures of the pelvis reduces pain significantly in elderly patients. Injury 2015;46(8):1631–6.
[41] Walker JB, Mitchell SM, Karr SD, Lowe JA, Jones CB. Percutaneous transiliac-transsacral screw fixation of sacral fragility fractures improves pain, ambulation, and rate of disposition to home. J Orthop Trauma 2018;32(9):452–6.
[42] Osterhoff G, Reise R, Riemer E, Hoch A, Fakler JKM, Heyde CE, et al. The pectineal ligament is a secondary stabilizer in anterior pelvic ring fractures - a biomechanical study. Injury 2022;53(2):334–8.
[43] Rommens PM, Wagner D, Hofmann A. Fragility fractures of the pelvis. JBJS Rev 2017;5(3).
[44] Rommens PM, Arand C, Hofmann A, Wagner D. When and how to operate fragility fractures of the pelvis? Indian J Orthop 2019;53(1):128–37.
[45] Apivatthakakul T, Rujiwattanapong N. Anterior subcutaneous pelvic internal fixator (INFIX), Is it safe?" A cadaveric study. Injury. 2016;47(10):2077–80.
[46] Arduini M, Saturnino L, Piperno A, Iundusi R, Tarantino U. Fragility fractures of the pelvis: treatment and preliminary results. Aging Clin Exp Res 2015;27(Suppl 1):S61–7.
[47] Mosheiff R, Liebergall M. Maneuvering the retrograde medullary screw in pubic ramus fractures. J Orthop Trauma 2002;16(8):594–6.
[48] Arand C, Wagner D, Richards RG, Noser H, Kamer L, Gehweiler D, et al. Anatomical evaluation of the transpubic screw corridor based on a 3D statistical model of the pelvic ring. Sci Rep 2021;11(1):16677.
[49] Acklin YP, Zderic I, Grechenig S, Richards RG, Schmitz P, Gueorguiev B. Are two retrograde 3.5mm screws superior to one 7.3mm screw for anterior pelvic ring fixation in bones with low bone mineral density? Bone Joint Res 2017;6(1):8–13.
[50] Acklin YP, Zderic I, Buschbaum J, Varga P, Inzana JA, Grechenig S, et al. Biomechanical comparison of plate and screw fixation in anterior pelvic ring fractures with low bone mineral density. Injury 2016;47(7):1456–60.